




# Hemispheric language organization after congenital left brain lesions: A comparison between functional transcranial Doppler and functional MRI

Anna Maria Chilosi<sup>1</sup>, Sara Bulgheroni<sup>2</sup>, Marco Turi<sup>3,4,\*</sup> , Paola Cristofani<sup>1</sup>, Laura Biagi<sup>1</sup>, Alessandra Erbetta<sup>5</sup>, Daria Riva<sup>2</sup>, Anna Nigri<sup>5</sup>, Luigi Caputi<sup>6</sup>, Nicola Giannini<sup>7</sup>, Simona Fiori<sup>1</sup>, Chiara Pecini<sup>1</sup>, Francesca Perego<sup>2</sup>, Michela Tosetti<sup>1</sup>, Paola Cipriani<sup>1</sup> and Giovanni Cioni<sup>1,7</sup>

<sup>1</sup>Department of Developmental Neuroscience, IRCCS Stella Maris Foundation, Pisa, Italy

<sup>2</sup>Developmental Neurology Division, IRCCS The Foundation of C.Besta Neurological Institute, Milan, Italy

<sup>3</sup>Department of Translational Research on New Technologies in Medicine and Surgery, University of Pisa, Italy.

<sup>4</sup>Stella Maris Mediterranean Foundation, Chiaromonte, Potenza, Italy

<sup>5</sup>Department of Neuroradiology, IRCCS The Foundation of C.Besta Neurological Institute, Milan, Italy

<sup>6</sup>Department of Cerebrovascular Diseases, IRCCS The Foundation of C.Besta Neurological Institute, Milan, Italy

<sup>7</sup>Department of Clinical and Experimental Medicine, University of Pisa, Italy

This study investigated whether functional transcranial Doppler ultrasound (fTCD) is a suitable tool for studying hemispheric lateralization of language in patients with pre-perinatal left hemisphere (LH) lesions and right hemiparesis. Eighteen left-hemisphere-damaged children and young adults and 18 healthy controls were assessed by fTCD and fMRI to evaluate hemispheric activation during two language tasks: a fTCD animation description task and a fMRI covert rhyme generation task. Lateralization indices (LIs), measured by the two methods, differed significantly between the two groups, for a clear LH dominance in healthy participants and a prevalent activation of right hemisphere in more than 80% of brain-damaged patients. Distribution of participants in terms of left, right, and bilateral lateralization was highly concordant between fTCD and fMRI values. Moreover, right hemisphere language dominance in patients with left hemispheric lesions was significantly associated with severity of cortical and subcortical damage in LH. This study suggests that fTCD is an easily applicable tool that might be a valid alternative to fMRI for large-scale studies of patients with congenital brain lesions.

\*Correspondence should be addressed to Marco Turi, Section of Human Physiology – Department of Translational Research on New Technologies in Medicine and Surgery, University of Pisa, Via Roma 55, Pisa 56100, Italy (email: turimarc@gmail.com).

Cerebral lateralization of function has been a topic of intense study within the language literature. Up to now, the gold standard measurement of cerebral dominance has been obtained by an intracarotid amobarbital injection procedure (Isaacs, Barr, Nelson, & Devinsky, 2006; Knecht *et al.*, 1998; Milner, Branch, & Rasmussen, 1962), but this tool, due to its invasiveness, is usually limited to patients undergoing neurosurgery (Somers *et al.*, 2011).

Lateralization indices (LIs) measured with functional magnetic resonance imaging (fMRI) have shown to be highly correlated with LIs measured by means of intracarotid amobarbital injection procedures (Abou-Khalil, 2007; Aldenkamp *et al.*, 2003; Binder *et al.*, 1996). Direct concordance between fMRI and intra-operative electrocorticography for language localization has also been reported (Maldjian, Liu, Hirschorn, Murthy, & Semanczuk, 1997; Rutten, Ramsey, van Rijen, Alpherts, & van Veelen, 2002). Over the last decade, fMRI has started to replace the Wada technique in pre-surgical clinical assessments, but this is not always applicable because of movement artefacts and high cooperative demands.

More recently, functional transcranial Doppler ultrasound (fTCD) has been proposed as a reliable alternative method for measuring cerebral lateralization during speech in both adults and children (Knake *et al.*, 2003). This portable technique is more economical compared to fMRI and can be used on young children and subjects with reduced cooperativeness (Bishop, Watt, & Papadatou-Pastou, 2009; Chilosi *et al.*, 2014; Deppe, Ringelstein, & Knecht, 2004). fTCD assesses cerebral lateralization by comparing changes in mean blood flow velocity in middle cerebral arteries (MCAs) during domain-specific neuropsychological tasks.

Similar to fMRI, fTCD has been shown to be correlated in healthy adults and in some patients with classic measures of hemispheric lateralization such as the Wada test (Abou-Khalil, 2007) and fMRI (Deppe *et al.*, 2000; Haag *et al.*, 2006; Hattemer *et al.*, 2011; Jansen *et al.*, 2004; Somers *et al.*, 2011). fTCD has good temporal resolution and provides continuous information about event-related changes in cerebral blood flow associated with functional cortical activation (Deppe *et al.*, 2000). It is non-invasive and is well suited for children (Bishop *et al.*, 2009; Haag *et al.*, 2010). In 2009, Bishop *et al.* created an fTCD animation description task designed to be particularly engaging for children. It has been demonstrated that this animation description task has good split-half reliability both in children and adults and that LI obtained using this paradigm correspond well with LI obtained using more standard language production paradigms, such as word generation ( $r = .47$ ) and picture description ( $r = .62$ ).

Comparison between fTCD and fMRI measurements of language lateralization, carried out on healthy adults and single cases, have revealed significant correlations between the two procedures, but to our knowledge, no data are currently available relative to either healthy or brain-damaged children.

In this study, hemispheric language lateralization using fTCD and fMRI in children and young adults with congenital focal brain lesions (CFBLs) of the left hemisphere (LH) was compared to an age- and ability-matched control group. The study of CFBL patients also provides an opportunity to examine reorganization of language function and early brain plasticity. Since the nineties, atypical hemispheric lateralization for language (in terms of a shift of language processing to the right hemisphere) has been demonstrated in children with congenital left hemispheric lesions by dichotic listening tests (Brizzolara *et al.*, 2002; Bulgheroni, Nichelli, Erbetta, Bagnasco, & Riva, 2004; Carlsson, Hugdahl, Uvebrant, Wiklund, & von Wendt, 1992; Chilosi *et al.*, 2005; Isaacs *et al.*, 2006) and by fMRI (Guzzetta *et al.*, 2008; Lazar *et al.*, 2000; Liegeois *et al.*, 2004; Muller *et al.*, 1999; Raja

Beharelle *et al.*, 2010; Staudt *et al.*, 2001). However, the relatively few fMRI studies on cortical language (re)organization on individuals with LH brain lesions have led to somewhat conflicting results, showing that damage to the LH does not always necessarily induce a shift of language representation to the right hemisphere (Liegeois *et al.*, 2004; Raja Beharelle *et al.*, 2010).

In contrast to classic models of right hemisphere compensatory activity after early brain injury, Liegeois *et al.* (2004) showed that proximity of lesion to cortical language areas is not always a good predictor of lateralization patterns. Even left Broca's area damage did not lead to right dominance for language. However, it is important to point out that all the patients in this study suffered from drug-resistant seizures, due to early LH lesions of heterogeneous aetiology. These factors could have determined different hemispheric language lateralization patterns with respect to those observed in patients without drug-resistant epilepsy and with vascular aetiology of damage. In a fMRI study on adolescents with early focal brain injury, due to pre- or perinatal stroke, Raja Beharelle *et al.* (2010) reported that right hemisphere compensatory language activation did not occur in all patients and depended more on type rather than size of lesion.

Feasibility and validity of fTCD for studies of hemispheric language lateralization in paediatric populations with congenital focal brain lesions have never been assessed and might bear several advantages for neuropsychological mapping of lateralization of high cortical functions both in a clinical and research setting, thus leading to the possibility of easily testing children across a wide age range.

From a clinical perspective, evaluation of hemispheric language dominance and its relation to type and severity of lesion may help determine possible early risk indices of long-term language outcomes.

The aims of this study were as follows: (1) to evaluate whether fTCD is suitable for determining hemispheric lateralization of brain activation during a language task in individuals with congenital LH lesions; (2) to assess concordance between fTCD and fMRI; (3) to investigate the relationship between language LI obtained by the two methods and type and severity of brain lesions.

## Methods

### Participants

Nineteen patients with congenital LH lesions were examined. One patient was excluded due to an insufficient signal through the temporal bone window during fTCD acquisition. The final sample included 18 participants with CFBL and 18 healthy controls matched for age and non-verbal intelligence level (see Table 1). The two groups did not differ statistically in mean age, CFBL mean age = 13.3 years,  $SD = 4.27$  years; controls' mean age = 14.02 years,  $SD = 3.5$  years;  $t(34) = -.53$ ,  $p = .61$ , effect size reliability  $d = .18$ , and in non-verbal IQ (CFBL non-verbal IQ mean = 92,  $SD = 11.3$ ; controls' non-verbal IQ mean 97,  $SD = 14.08$ ;  $t(34) = 1.17$ ,  $p = .24$ , effect size reliability  $d = .39$ ).

Congenital focal brain lesions patients were recruited from a larger population of subjects affected with congenital hemiplegia. Inclusion criteria were the following: presence of a focal brain lesion (documented by standard structural MRI) due to pre- or perinatal adverse events, age-appropriate non-verbal IQ (assessed by Wechsler Intelligence Scale), normal hearing and absence of behavioural disorders. Patients with multiple brain lesions determined by MRI, or afflicted with severe or uncontrollable seizures were

**Table 1.** Demographic characteristics of patients and controls

	CFBL Mean (SD) Range	Controls Mean (SD) Range	Statistics	
			t	p
CA at fMRI (years)	13.12 (4.1) 7.6–25.1	13.9 (3.5) 9.4–25.1	0.61	.54
CA at fTCD (years)	14.36 (3.38) 9.8–25.1	14.03 (3.6) 9.4–5.1	0.28	.77
Performance IQ	92 (11.3) 72–110	97 (14.08) 80–134	1.17	.24
Verbal IQ	93.7 (13.5) 66–123	110 (20) 71–138	−3.10*	.006*

Notes. CA = Chronological age; CFBL = congenital focal brain lesion; fMRI = functional magnetic resonance imaging; fTCD = functional transcranial Doppler sonography; IQ = intelligent quotient.

\*Significant difference at  $p < .05$ .

excluded. All control participants were right-handed as determined by the Edinburgh Handedness Inventory questionnaire with a mean score  $>0.60$  (Oldfield, 1971). They did not have any developmental or academic disabilities. Parental consent and child assent were obtained in all cases. The study was approved by the authorized Ethics Committee (Number 36/2010).

### Procedures

All CBFL and control participants underwent fTCD and fMRI assessment.

#### *fTCD assessment apparatus*

Bilateral blood flow velocity in MCAs was measured simultaneously by a commercially available Doppler ultrasonography device (DWL Multidop T2: manufacturer, DWL Elektronische Systeme, Singen, Germany), using two 2-MHz transducer probes mounted on a flexible headset. For the experimental presentation and stimulus design, Presentation software (Neurobehavioral Systems, Inc., Albany, CA, USA) was used. Visual stimuli (videoclips) were presented on a standard 15" Dell laptop, which sent parallel port marker pulses to the Multidop system to signal the start of each epoch.

#### *fTCD data recording*

Cerebral blood flow velocity (CBFV) in MCAs was recorded bilaterally during the entire experiment. Insonation techniques, including correct identification and depth adjustment, have been published elsewhere (Ringelstein, Kahlscheuer, Niggemeyer, & Otis, 1990).

#### *fTCD language paradigm*

An animation description task (FreezeFoot Story), developed by Bishop *et al.* (2009), which includes 30 twelve-second silent video clips was used during fTCD acquisition. All

original animated '.avi' files were kindly provided by Professor Bishop and were sequenced into a single movie, run by the 'Presentation Program'.

As described by the authors (Bishop *et al.*, 2009) and in a previous study conducted with fTCD (Chilosi *et al.*, 2014), during each videoclip, participants silently observed a 12-s cartoon, and then, cued by an acoustic signal and a visual question mark, were asked to describe for 10 s what they had seen. Each trial ended with an 8-second silent rest period. The 12 s during which the participants watched the videoclip constituted the baseline period, whereas the 10-second description time was considered the activation period. The Multidop system recorded both baseline and activation periods. Mean velocity of blood flow during activation period was then compared to that of baseline. All participants received detailed instructions and training prior to the experiment. For each participant, the experiment lasted about 30 min.

#### *FTCD data analysis*

FTCD data were analysed using Average software (Deppe, Knecht, Henningsen, & Ringelstein, 1997). CBFV data were segmented into epochs, related to marker signals and averaged. Epochs containing CBFV values outside the range of 60–140% of the mean were excluded as measurement artefacts. Transformation to relative units was performed using the following formula  $dv = 100 (V(t) - V_{pre.mean}/V_{pre.mean})$  where  $V(t)$  is the CBFV over time and  $V_{pre.mean}$  is the mean velocity during the 12-second period of silently watching videos.

LIs is defined as the difference in blood flow velocity between the left and right MCAs in a 2-second window centred on the peak value of this difference within the period of interest (4s–10s).

Lateralization indices quantifies the average per cent difference of relative CBFV changes during activation period in comparison with baseline. Positive values correspond to greater LH activation, indicating LH asymmetry for language, while negative values indicate right hemisphere lateralization. Lateralization indices (LI) standard error of the mean (SEM) represents the variability between laterality indices over accepted epochs; thus, a lower SEM of lateralization index accounts for higher performance continuity and higher quality of Doppler signal throughout the investigation. One-sample *t*-test was used to verify whether LI value was significantly left- or right-lateralized for each participant. Following Knecht *et al.* (1998), when the one-sample test did not reach significance, the participant was considered bilateral lateralized.

#### *Structural MRI*

Structural MRI was obtained for each participant using 1.5-tesla MR scanners (GE; Signa Horizon 1.5, Milwaukee, WI, USA, and Siemens Avanto, Erlangen, Germany). High-resolution structural sagittal, axial, and coronal T1- and T2-weighted anatomical and FLAIR images were acquired using a 0.9-mm isotropic 3D T1 BRAVO sequence. Structural MR images were classified by a paediatric neurologist (SF) and a neuroradiologist (AE) blinded to clinical features and history. According to the Krageloh-Mann classification system (Krageloh-Mann & Horber, 2007), three types of brain lesion were identified: periventricular white matter (PWM) lesions, cortical and deep grey matter (CDGM) lesions and brain maldevelopments (BM). Lesions were classified as miscellaneous if they did not fit any Krageloh-Mann category. Brain lesion severity on all

structural MR images was determined by one of the authors (SF) using a recently developed semiquantitative scale (Fiori & Guzzetta, 2015; Fiori *et al.*, 2014) which demonstrated reliability and validity. This semiquantitative scale is based on a visual approach of lesion appearance on MRI scan. Brain lesion is firstly represented on a six-axial slices graphical template superimposed onto Talairach atlas for lobar topography. Also, basal ganglia, cerebellum and corpus callosum are included in the scoring system. In the hemispheres, three layers on the template are delineated, corresponding to periventricular, middle, or cortico-subcortical white matter (for template reproduction, see appendix of original publication in Fiori *et al.*, 2014). According to the involvement of different brain structures and hemispheric layers, raw scores for each lobe of the brain are systematically calculated (lobar scores). Higher scores on the semiquantitative scale represent more severe pathologies. Lobar scores, with a maximum of 3 for each lobe, are calculated separately for frontal, temporal, parietal, and occipital lobes, respectively. The right or left hemispheric score (HS) is the sum of lobar scores within each hemisphere (maximum score of 12 for each hemisphere). The basal ganglia and brainstem score (BGBS) is assigned to left and right subcortical structures (basal ganglia, thalamus, brainstem and posterior limb of the internal capsule) (maximum score of 5 on each side). The right or left hemispheric summary score (HSS) is the sum of HS and BGBS scores within each hemisphere (maximum score 17 on each side). The global score (GS) is the sum of right and left HS, BGBS, corpus callosum, and cerebellum scores (maximum of 40).

#### *Functional MRI*

Functional MR imaging (fMRI) protocol included the following sequences: sagittal volumetric T1-weighted magnetization-prepared rapid acquisition gradient-echo (TR = 1640 msec, TE = 2.28 msec, flip angle: 12°; 160 sections with isovolumetric resolution of 1.0 mm<sup>3</sup>) and a T2\*-weighted BOLD echo-planar imaging (EPI) gradient-echo sequence (flip angle 90°, TR = 3950 msec, TE = 52 msec; FOV = 256 mm<sup>2</sup>, 128 × 128 matrix and nominal resolution 2.0 × 2.0 × 4.0 mm<sup>3</sup>). A series of 120 volumes, after discarding the 3 initial dummy scans, was obtained in the transverse plane parallel to the anteroposterior commissural line.

All functional data sets were analysed by two of the authors (LB and AE) both blinded to results obtained by fTCD. For each patient, a significance threshold for the pattern of activation of  $q(\text{FDR}) < .001$  was applied.

#### *fMRI stimuli*

The paradigm consisted of repeated cycles of on- and off-periods of a single task (block design, time-course series of 30 s each, 6 cycles, total time acquisition 6 min). Stimuli were generated by the software package Presentation (Neurobehavioral Systems, Inc.) and displayed through liquid crystal goggles (VisuaStim XGA Resonance Technology Inc, Northridge, CA, USA; at a resolution of 800 × 600 voxels, subtending 30° × 22.5° at an apparent distance of 1.5 m, with mean luminance of 30 cd/m<sup>2</sup>). Luminance, colour, shapes (Arial font), and size (font '96') were carefully balanced between task and rest. Organization of language was studied using a covert rhyme generation task. Participants were asked to silently generate a word rhyming with a two-syllable word presented on the screen. Stimuli were presented at 0.2 Hz (1/5 s), 6 words per block, for a total of 18 words. Rest condition consisted of passively watching of a string of capital X letters

(XXXX) presented at the same frequency as task stimuli. Participants received detailed instructions and training prior to experiment.

#### *fMRI data analysis*

Post-processing and statistical analysis of functional images were performed using the software package Brain Voyager QX (Brain Innovation, Maastricht, the Netherlands). After realignment of all volumes, data were pre-processed (spatial smoothing, temporal filtering, linear trend removal) and the first functional volume was co-registered to the respective high-resolution T1 anatomic images of each participant.

Statistical analysis was performed on every participant in order to assess language lateralization and compare fMRI and fTCD results. For each participant, statistical analysis was performed using a general linear model. As a basic function, we chose a box-car waveform, synchronous with the stimulus presentation and convoluted with a synthetic hemodynamic response function (Boynton, Engel, Glover, & Heeger, 1996). Pattern of activation for each patient was obtained individually applying a threshold of  $p < .005$  uncorrected,  $q(\text{FDR}) < .01$ .

From activation patterns, elicited areas were firstly classified, and for each one, the number of significant voxels was determined. LI was obtained by computing  $LI = (nL - nR)/(nL + nR)$ , where nL and nR are the number of activated voxels in the left (LH) and in the right (RH) hemisphere, respectively (Fernandes, Smith, Logan, Crawley, & McAndrews, 2006). The absolute value .20 was used as threshold for definite lateralization (Seghier, 2008). Participants with a positive index ( $LI > .20$ ) were considered left-lateralized for language, while those with a negative index ( $LI < -.20$ ) were considered as right-lateralized. Values of  $|LI| \geq .20$  represent a 'bilateral' or uncertain activation.

For each participant, two LIs were calculated. The first one (fMRI WhB) was obtained on the entire brain, determining the number of significantly activated voxels in the whole LH and right hemisphere, respectively. The second one (fMRI LaA) was computed in the two hemispheres considering the number of voxels in areas restricted to the language circuits: inferior frontal gyrus, middle frontal gyrus, pre-central gyrus, insula, middle temporal gyrus, superior temporal gyrus, supramarginal gyrus, angular gyrus and cingulated gyrus.

#### *Comparison between LIs determined by fTCD and fMRI*

Correlation between LI measures was assessed by a bivariate analysis. Agreement between fTCD and fMRI was evaluated by overall concordance and the Kappa statistic. The 95% confidence interval (CI) for overall agreement was calculated by the exact binomial method and, for the Kappa statistic, by an analytical method in the case of dichotomous variables (Fleiss, 1981) or bootstrap for multiple categories variables (Efron & Tibshirani, 1991; Lee & Fung, 1993). For the bootstrap method, 10,000 samples were used. As a benchmark for the Kappa statistic, the Landis and Koch scale (Landis & Koch, 1977) was used (0 = poor; 0 to .20 = slight; .21 to .40 = fair; .41 to .60 moderate; .61 to .80 substantial; .81 to 1.00 = almost perfect). Statistical analysis was performed by the STATA 10 statistical package (StataCorp LP, College Station, TX, USA).

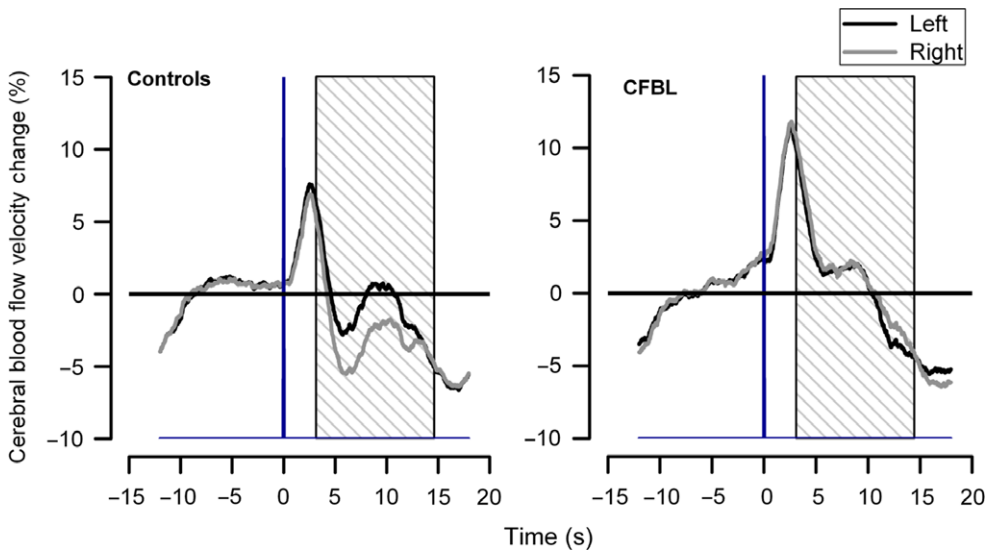
In order to investigate the relationship between language lateralization and lesion severity, a bivariate correlation was carried out on the CFBL group.

## Results

### fTCD

For fTCD, the number of accepted epochs did not differ between participants with CFBL (mean = 25.7,  $SD = 2.45$ ; range: 20–28) and controls (mean = 26.5,  $SD = 3.35$ , range: 22–30;  $t(34) = .817$ ,  $p = .41$ ; effect size reliability  $d = .27$ ). In order to evaluate the reliability of fTCD data, a split-half reliability analysis was carried out on CFBL and controls showing that reliability was sufficiently high for both groups (CFBL  $r = .72$ ,  $p < .01$ ; controls  $r = .92$ ,  $p < .001$ ) and did not differ significantly ( $Z = -1.87$ ,  $p = .061$ ). For each participant, the SEM of lateralization index was also calculated and comparison between CFBL and control groups was performed. The mean SEM of the two groups (CFBL mean = .80,  $SD = 0.36$ ; controls' mean = .62,  $SD = 0.23$ ) did not differ significantly ( $t(34) = 1.75$ ,  $p = .09$ , effect size reliability  $d = .59$ ), although, given the small sample size, it is not possible to definitely conclude for a comparable signal quality and performance continuity in both groups.

Results from the fTCD paradigm showed the presence of a LH lateralization in controls (LI mean = 3.039,  $SD = 2.33$ ) and a right hemisphere lateralization in CFBL patients (LI mean = -1.35,  $SD = 2.33$ ) (see Figure 1). Statistical comparisons between the two groups revealed that LI indices differed significantly between CFBL patients and controls ( $t(34) = -5.103$ ,  $p < .001$ , effect size reliability  $d = .79$ ). At the group level, mean LI significantly differed from zero both in control ( $t(17) = 5.517$ ,  $p < .001$ , effect size reliability  $d = 1.31$ ) and CFBL groups ( $t(17) = -2.047$ ,  $p < .05$ , effect size reliability  $d = -.48$ ) but in this latter case although, given the small sample size, this result cannot be interpreted in terms of clear right hemisphere lateralization. All fTCD data analysis was performed by one of the authors (MT).



**Figure 1.** Average activation across epochs for left and right middle cerebral arteries in the control and congenital focal brain lesions group. Black and grey curves refer to the signal in the left and right medial cerebral arteries, respectively. The vertical line indicates the time at which the linguistic task started. The grey areas with oblique lines refer to blood flow velocity changes during the activation period.



## fMRI

The rhyme generation task elicited activation of reorganized right or left language networks, as shown by Figure 2B in two representative patients, one with CDGM, the other with PWM lesion, and right or left hemispheric dominance, respectively. The patient with CDGM lesion is representative of right hemisphere activation in homotopic language areas.

In agreement with the results of fTCD, mean LI values for the two fMRI indices were positive in the control group (WhB-LI mean = .54,  $SD = 0.26$ ; LaA-LI mean = .56,  $SD = .26$ ) and negative in the CFBL group (WhB-LI mean =  $-0.33$ ,  $SD = .52$ ; LaA mean =  $-0.23$ ,  $SD = .60$ ). Differences between CFBL and control mean fMRI LIs were statistically significant, fMRI WhB  $t(34) = -6.39$ ,  $p < .001$ , effect size reliability  $d = 2.11$ ; fMRI LaA  $t(34) = -5.09$ ,  $p < .001$ , effect size reliability  $d = 1.70$ .

At the group level, mean fMRI LIs significantly differed from zero in controls (fMRI WhB  $t(17) = 9.064$ ,  $p < .0001$ , effect size reliability  $d = 2.13$ ; fMRI LaA  $t(17) = 8.938$ ,  $p < .0001$ , effect size reliability  $d = 2.10$ ). Instead, in the CFBL group, clear right hemisphere language dominance was found for fMRI WhB ( $t(17) = -2.711$ ,  $p < .01$ , effect size reliability  $d = -.63$ ), but not for fMRI LaA ( $t(17) = -1.658$ ,  $p = .11$ , effect size reliability  $d = -.38$ ). Individual data relative to fTCD and fMRI LIs in the CFBL and control group are reported in Tables S1 and S2 of Supporting Information.

### *Laterality Indices' correlation and concordance between fTCD and fMRI*

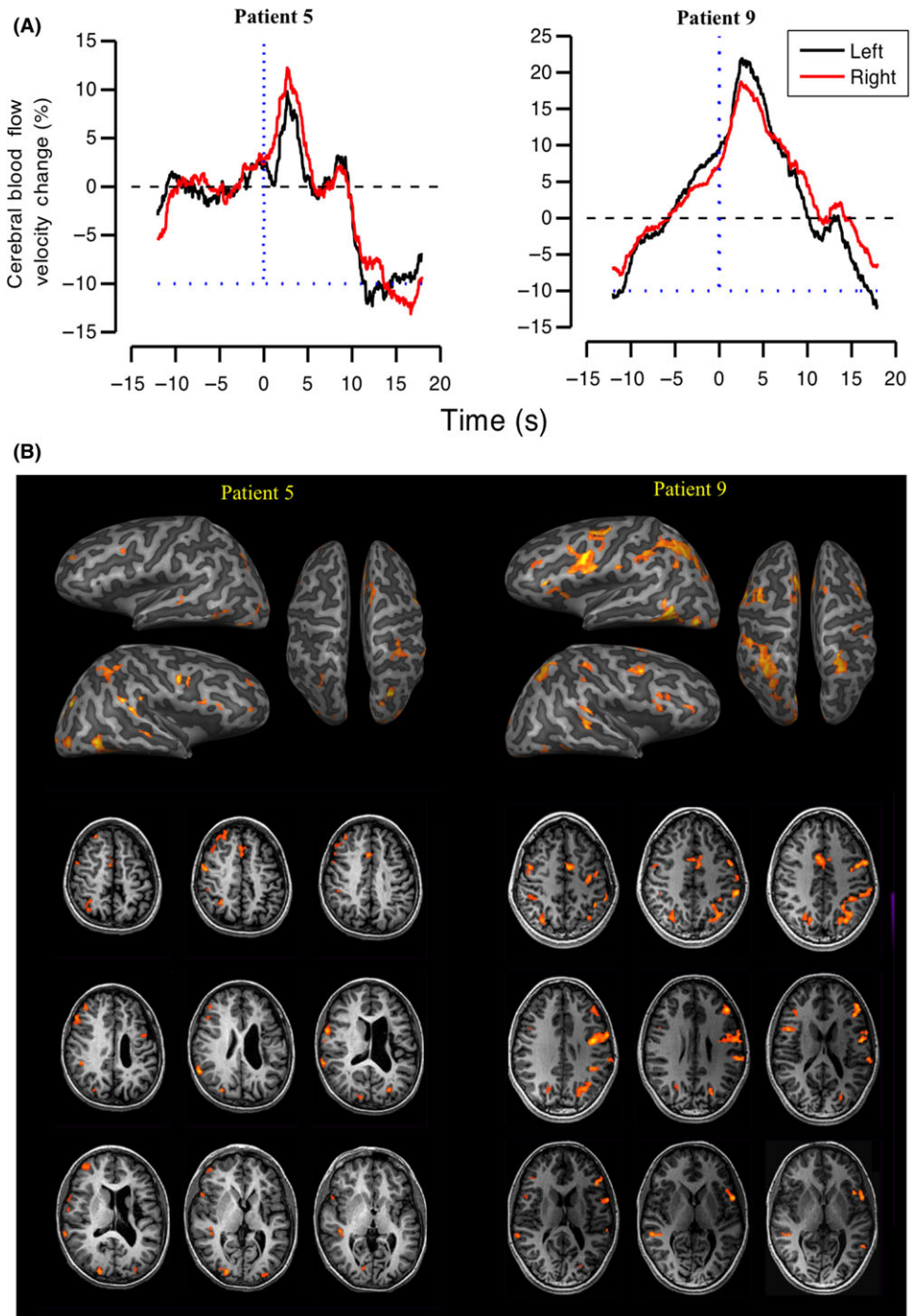
Correlations between fTCD and fMRI LIs were calculated using Pearson coefficient ( $r$ ) for the whole sample and separately for CFBL and control group.

As shown in Figure 3, we found a statistically significant correlation between fTCD LI and the two fMRI LIs (A: LI-WhB  $r = .70$ ,  $p < .0001$ ; B: LI-LaA  $r = .64$ ,  $p < .0001$ ) in the whole sample. Separate analyses within the CFBL group also showed a significant correlation between fTCD and fMRI LIs (WhB  $r = .73$ ,  $p < .001$ ; LaA  $r = .60$ ,  $p < .001$ ). However, looking at the correlations between fTCD and fMRI LIs in the control group, no statistically significant correlation (WhB  $r = -.25$ ,  $p = .31$ ; LaA  $r = -.21$ ,  $p = .39$ ) was found. This was probably because the sample included only right-handed participants and consequently the distribution of LIs in the control group was 'right (positively)-shifted' (Somers *et al.*, 2011) and less variable compared to CFBL group. Moreover, in the whole sample correlation coefficients of the two fMRI LIs and fTCD LI did not differ significantly ( $Z = .44$ ,  $p = .65$ ).

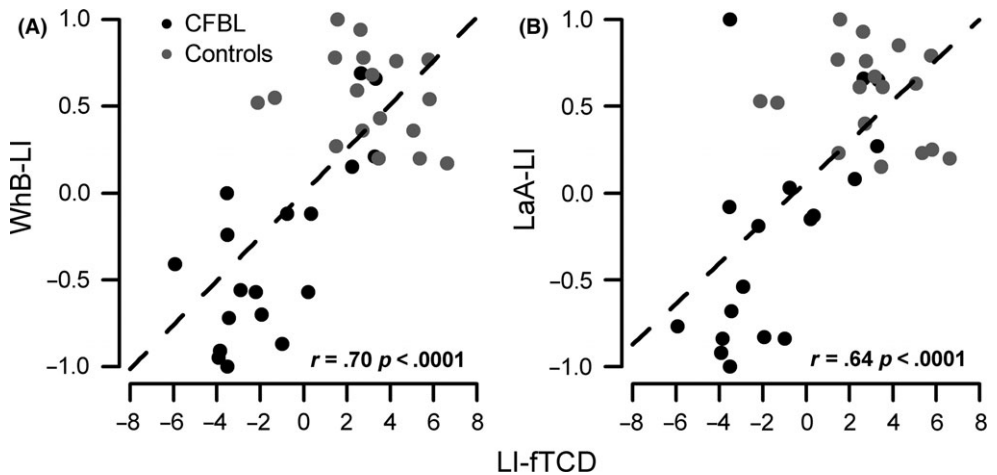
Distribution of LIs for fTCD and fMRI and concordance between LI values obtained from the two techniques were assessed by computing LI magnitude (degree of lateralization, according to statistically defined threshold). Concordance between indices was expressed as percentage of cases in which LIs agreed. An exact binomial CI for the percentage was also computed.

As shown in Table 2, percentages of agreement between fTCD and the two fMRI LIs ranged from 83% to 89% in controls, and from 78% to 83% in CFBL patients. According to Landis and Koch Kappa's benchmark scale (Landis & Koch, 1977), strength of agreement was 'almost perfect' in the former and 'substantial' in the latter.

In order to verify the presence of task-specific laterality effects, ten CFBL patients and nine controls were administered two fTCD tasks, the animation task and the same rhyme generation task used for fMRI. Spearman correlational analysis showed significant correlations between the two fTCD paradigms ( $r = .87$ ,  $p < .001$ ), and between fTCD rhyme generation and fMRI WhB and LaA LIs (respectively,  $r = .685$ ,  $p < .01$  and  $r = .91$ ,  $p < .01$ ).



**Figure 2.** Examples of fTCD curves (A) and fMRI images (B) from two patients. The patients differ for lesion characteristics: the one on the left (patient 5) has a cortical deep grey matter lesion and the one on the right (patient 9) a periventricular white matter lesion. Note the concordance between fTCD (A) and fMRI (B) activation in the right (patient 5) or left (patient 9) hemisphere.



**Figure 3.** fMRI WhB (A) and fMRI LaA (B) LIs as a function of fTCD LI for all participants (controls: grey; congenital focal brain lesions: black). The black dashed line shows the correlations across all participants.

**Table 2.** Concordance between laterality indices at fTCD and fMRI

		Controls			CFBL		
		fTCD LI			fTCD LI		
		R	L	B	R	L	B
fMRI WhB	R	0	0	0	10	0	1
	L	2	15	0	0	3	1
	B	0	1	0	1	0	2
Agreement %		.83			.83		
Exact 95% CI		.58–.96			.58–.96		
Kappa		NA			.70		
Exact 95% CI					.34–1.00		
fMRI LaA	R	0	0	0	8	1	2
	L	1	16	0	0	3	1
	B	0	1	0	0	0	3
Agreement %		.89			.78.9		
exact 95% CI		.65–.98			.54.4–.93.9		
Kappa		NA			.64		
Exact 95% CI					.33–.91		

Notes. LI = Lateralization index; R = right; L = left; B = bilateral; CFBL = congenital focal brain lesion; fTCD = functional transcranial colour Doppler sonography; fMRI WhB = functional magnetic resonance imaging-whole brain; fMRI LaA = functional magnetic resonance imaging language areas; na = not applicable; CI = confidence interval.

#### *Relationship between language laterality indices and verbal performance*

Linguistic measures available for the whole sample were Verbal IQ, and vocabulary and comprehension subscales scores at WISC-III.

CFBL patients, as a group, performed within normal limits (see Table 1), but scores were significantly lower than controls (Verbal IQ  $t(34) = -2.89$ ,  $p < .01$ , effect size

reliability  $d = .95$ ; Vocabulary  $t(34) = -3.9, p < .001$ , effect size reliability  $d = 1.44$ ; Comprehension  $t(34) = -2.71, p < .01$ , effect size reliability  $d = 1.35$ ).

In the CBFL group, fTCD LI significantly correlated with Verbal IQ ( $r = .521, p < .05$ ) and Vocabulary score ( $r = .505, p < .05$ ), showing that higher (positive) LI values were associated with better linguistic performance. On the other hand, no significant correlations were found between fMRI LIs and any measure of language performance.

### Type of brain lesions and language laterality indices

All patients had a left-sided lesion that involved CDGM in eight cases, and PWM in 10 (see Table S1 of Supporting Information for individual data). Left hemisphere Summary Score (L-HSS) was significantly higher ( $t(16) = 2.29, p = .036$ , effect size reliability  $d = 1.31$ ) in CDGM (mean = 9.6,  $SD = 2.7$ ) compared to PWM lesions (mean = 6.7,  $SD = 1.4$ ), whereas there were no differences for averaged Left Hemispheric Score (HS  $t(16) = 1.8, p = .08$ , effect size reliability  $d = .86$ ), Global Severity Score (GS  $t(16) = -1.24, p = .23$ , effect size reliability  $d = .61$ ) and Left Basal Ganglia and Brainstem Score (L-BGBS  $t(16) = -1.085, p = .29$ , effect size reliability  $d = .50$ ).

All patients with CDGM lesions presented right hemisphere language dominance at fTCD, with the exception of number 1 who had BM and showed bilateral activation. At fMRI, the pattern was similar for whole brain (WhB), whereas there was a higher number of participants with bilateral activation for language areas (LaA).

As reported in Table 3, patients with PWM lesions showed a more variable pattern, with right hemisphere language dominance occurring in 40% of participants for both fTCD and fMRI LaA, and in 30% for fMRI WhB.

### Severity of lesion and language LIs

Statistical analysis was conducted to compare lesion severity scores between patients with and without right hemisphere language dominance. In participants with right hemisphere language dominance, left HSS was significantly higher for both fMRI, WhB,  $t(12) 2.3, p < .05$ , effect size reliability  $d = 5.33$ ; LaA,  $t(10) 2.47, p = .03$ , effect size reliability  $d = 1.48$ , and fTCD ( $t(13) = 3.03, p < .05$ , effect size reliability  $d = 1.96$ ). For fTCD, also left HS was significantly higher in patients with right (mean = 6.5,  $SD = 2.1$ ),

**Table 3.** Distribution of lateralization indices in patients with CDGM and PWM lesions obtained with fTCD and fMRI

	fTCD LI				fMRI WhB-LI				fMRI LaA-LI			
	LI Mean (SD)	R (N)	L (N)	B (N)	LI Mean (SD)	R (N)	L (N)	B (N)	LI Mean (SD)	R (N)	L (N)	B (N)
CDGM N (8)	-1.92 (2.4)	7	0	1	-.49 (.51)	7	0	1	-.40 (.51)	5	0	3
PWM N (10)	-.78 (3.19)	4	4	2	-.17 (.50)	3	4	3	-.07 (.68)	4	3	3

Note. CDGM = Cortical and deep grey matter; PWM = periventricular white matter; LI = lateralization index; R = right; L = left; B = bilateral; fMRI = functional magnetic resonance imaging; fTCD = functional transcranial colour Doppler sonography.

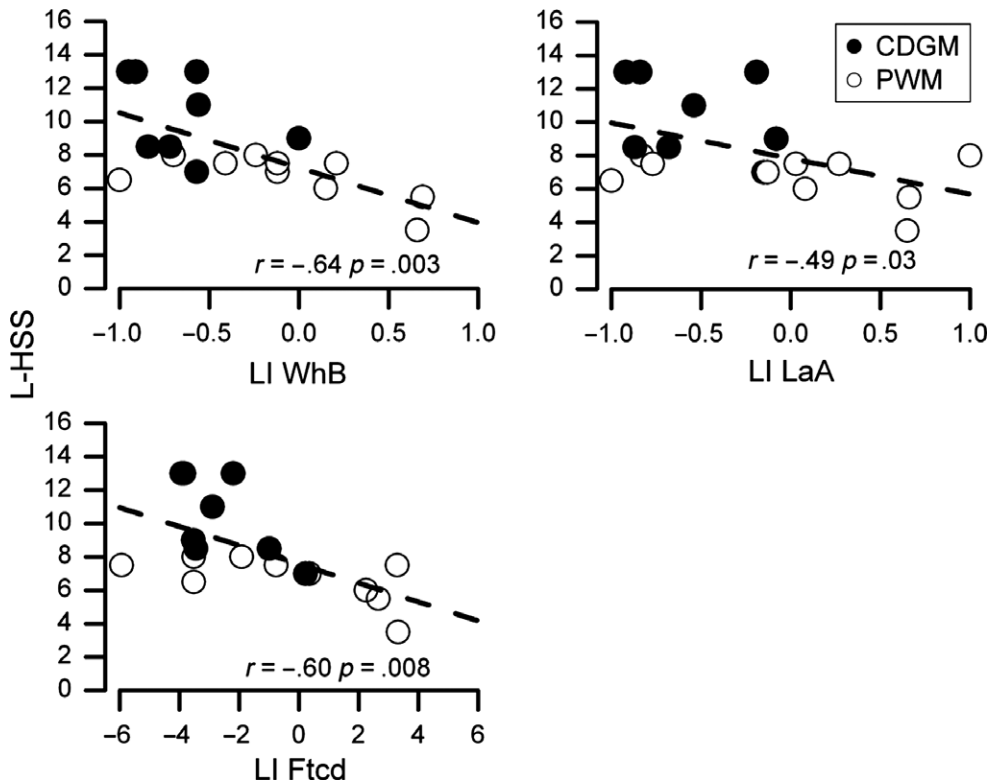
compared to left (mean = 3.6,  $SD = 1.3$ ) hemisphere language dominance ( $t(13) = 2.47$ ,  $p < .05$ , effect size reliability  $d = 1.66$ ).

These findings were confirmed by correlational analyses between hemispheric dominance and lesion severity, showing that, more severe hemispheric lesions were associated with higher negative LI values, indicative of more right-lateralized language (see Figure 4).

For fTCD, both left HS and left HSS were inversely correlated with LIs. For fMRI, LI indices inversely correlated with left HSS and also with left BGBS (Table 4). However, separate analyses on CDGM and PWM groups showed that inverse correlations between lesion severity and LI values were statistically significant (Bonferroni-corrected) in patients with cortical lesions, but not in patients with PWM lesions (CDGM: fTCD and left HSS:  $r = -0.87$ ,  $p < .01$ ; fMRI LaA and left BGBS:  $r = -.81$ ,  $p < .01$ ).

## Discussion

As stated in our first aim, this study has demonstrated that fTCD is a suitable tool for determining hemispheric lateralization of brain activation during a language task in people with congenital LH lesions.



**Figure 4.** Individual LIs for the three measures of language lateralization (fTCD, fMRI WhB, fMRI LaA) as a function of Left Hemisphere Summary Score (L-HSS). White dots indicate patients with cortical deep grey matter lesions (CDGM) and black dots patients with periventricular white matter lesions (PWM). Lines are best-fitting regressions considering all participants.

**Table 4.** Correlation between severity of lesion and fMRI and fTCD laterality indices

	WhB-LI	LaA-LI	fTCD LI	Left HSS	Left HS	Left BGBS
WhB-LI		<b>0.838</b> (0.000)	<b>0.735</b> (0.001)	− <b>0.647</b> (0.004)	−0.370 (0.131)	− <b>0.563</b> (0.015)
LaA-LI			<b>0.603</b> (0.008)	−0.493 (0.037)	−0.104 (0.681)	−0.402 (0.098)
fTCD LI				− <b>0.600</b> (0.008)	− <b>0.558</b> (0.015)	−0.337 (0.171)
Left HSS					<b>0.805</b> (0.000)	0.531 (0.023)
Left HS						0.056 (0.826)
Left BGBS						

Notes. Pearson correlation coefficients that reached significance are displayed in bold. Level of significance ( $p < .016$ ) was obtained after Bonferroni correction.

WhB-LI = fMRI whole brain laterality index. LaA-LI = fMRI language areas laterality index; Left HS = Left Hemispheric Score; Left HSS = Left Hemisphere Summary Score; Left BGBS = Left Basal Ganglia and Brainstem Score.

Previous research has shown that fTCD is a reliable alternative to fMRI in determining language hemispheric dominance in children and adults with normal and atypical development (Bishop, Holt, Whitehouse, & Groen, 2014; Bishop *et al.*, 2009; Chilosi *et al.*, 2014; Hodgson & Hudson, 2016; Whitehouse & Bishop, 2008). However, there is still relative scarcity of studies examining validity of this technique in comparison with other measurement methods. Moreover, previous studies have been carried out on small samples, due to complexity of designing this kind of research (Binder *et al.*, 1996; Deppe *et al.*, 2000; Knake *et al.*, 2003; Knecht *et al.*, 1998; Rutten *et al.*, 2002; Somers *et al.*, 2011; Wellmer *et al.*, 2008).

In this study, a group of brain-damaged children and young adults, and relative control group underwent fTCD and fMRI to evaluate hemispheric activation during execution of language tasks.

For fTCD, both groups showed similar intrasubject performance variability and stability of signal quality, as documented by comparable SEMs and fTCD signal values across all recording epochs. These findings and relatively high split-half correlation coefficients confirmed reliability of this procedure and its applicability to patients with congenital focal brain lesions, a population in which cerebral lateralization has never been specifically investigated by this method. Hemispheric lateralization for language differed significantly between CFBL patients and controls with a LH dominance in the control group and a prevalent activation of right hemisphere in CFBL patients. Interestingly, the shape of the fTCD curves in the two groups was different, suggesting possibly different neural substrates activated by the task, as reported by Meyer, Spray, Fairlie, and Uomini (2014).

For fMRI, the pattern of lateralization was similarly inverse to that of controls, with more than 80% of patients showing, as for fTCD, a non-left cerebral dominance for language. Distribution of participants in terms of right, left, and bilateral activation did not significantly differ between fTCD and fMRI measurements.

As hypothesized in the second aim, concordance between fTCD and fMRI LIs was strong for the entire sample. In the control group, strength of agreement between the two techniques was ‘almost perfect’ (according to Landis and Koch Kappa’s benchmark scale, 1977) for both fMRI WhB and LaA. In the CFBL group, strength of agreement was ‘almost perfect’ for fMRI WhB and ‘substantial’ for fMRI LaA.

These findings are significant considering the limits of this study, that is, the use of different fTCD and fMRI paradigms and inherent differences in methods of analysis of

these two techniques. The choice of an animation task, as a fTCD language paradigm, was motivated by significant correlations found with other language tasks (such as word generation and picture description, see Bishop *et al.*, 2009) and by results of a recent study carried out by Chilosi *et al.* (2014) that confirmed its feasibility and validity in children with language disorders. Moreover, to verify the presence of possible task-specific laterality effects, a subgroup of both CFBL and controls were administered two fTCD paradigms, the animation task and the same rhyme generation task used for fMRI. Results showed significant correlations of fTCD and fMRI LIs, suggesting that a similar activation pattern had occurred with the two different tasks.

Other studies (Bishop *et al.*, 2009; Payne, Gutierrez-Sigut, Subik, Woll, & MacSweeney, 2015) reported that the strength of lateralization may vary in relation to task type and demands (see Stroobant, Van Boxtael, & Vingerhoets, 2011). According to Bishop *et al.* (2009), the animation description task may place heavy demands on more complex brain circuitries involved in sentence production, compared to the rhyme generation task, which mainly involves phonological processing circuitries. However, because of poor spatial resolution, fTCD is not well suited for investigating activation patterns in terms of localization. So, it can only be speculated that the animation description task might involve a broader brain network than the rhyme generation one.

The higher degree of concordance between fTCD and fMRI whole brain, as compared to fMRI language areas, could be explained by considering the fact that fTCD measures changes in cerebral blood velocity in the left and right MCAs. These arteries provide blood to a large region of lateral cortices, thus spreading activation beyond language areas (Gibo, Carver, Rhoton, Lenkey, & Mitchell, 1981).

Prevalence of right hemisphere activation in CFBL is consistent with literature on language organization following congenital focal brain lesions (Lidzba & Staudt, 2008; Staudt *et al.*, 2001; Tillema *et al.*, 2008) and with previous studies carried out by our research group, using fMRI (Guzzetta *et al.*, 2008; Pecini *et al.*, 2011) and dichotic listening paradigm (Brizzolaro *et al.*, 2002; Chilosi *et al.*, 2005).

Concerning behavioural consequences of language (re)organization in the right hemisphere, it is worth noting that CFBL patients' language performances were within the normal limits, suggesting indeed that the two hemispheres are able to carry out similar functions in the case of focal brain lesion. Nevertheless, CFBL patients had mean Verbal IQ, Vocabulary, and Comprehension scores significantly lower than controls, showing that the degree of recovery and compensatory organization carries a cost in terms of language efficiency. In our patients, better linguistic performances were associated with LH language dominance, whereas atypical language lateralization was associated with lower verbal skills.

These results are not in keeping with current assumptions on typically developing children (Bishop *et al.*, 2014; Knecht *et al.*, 2001) and on patients with congenital neurodevelopmental disorders (Bishop *et al.*, 2014; Illingworth & Bishop, 2009; Whitehouse & Bishop, 2008) which state that atypical language lateralization (in terms of LIs) is not necessarily associated with impaired performance during experimental tasks.

Our data replicate the results of a study by Raja Beharelle *et al.* (2010) on hemispheric language lateralization in adolescents who had sustained pre- or perinatal LH stroke. Using a fMRI fluency task, a 'direct relationship between brain activity and individual language outcome' was found. More specifically, activations in left inferior frontal and (bilaterally) in left and right superior temporal-parietal regions were associated with better language skills, supporting the assumption that left frontal circuitries play a critical role in language acquisition.

The third purpose of this study aimed at enhancing data from previous research on the relationship between cerebral language organization, and type and severity of brain lesion. Using new MRI-based scoring scales of brain injury severity in children with unilateral cerebral palsy (Fiori *et al.*, 2014), we found that (re)organization of language in right hemisphere was significantly related to type and severity of lesion and this finding was equally evidenced by fMRI and fTCD. Regarding type of brain damage, in the case of cortical deep grey matter lesions, right hemisphere language dominance was present in 90% of patients for fTCD and fMRI WhB and in 67% for fMRI LaA. No one presented LH dominance for language, converse to results reported in a study by Liegeois *et al.* (2004), in which five out of 10 epileptic patients showed left hemispheric language dominance, probably related to the effects of drug-resistant seizures. It is worth noting that in our sample no patient presented severe intractable epilepsy.

More than one-third of patients with PWM lesions instead maintained typical LH dominance for language for both fTCD and fMRI, suggesting a left intrahemispheric (re)organization of language. A quite similar relationship between language (re)organization and type of lesion can be observed in the patients with congenital LH brain damage recently described by Knecht and Lidzba (2016). These patients showed a prevalence of right hemisphere language dominance in the case of cortical, compared to PWM lesions.

In addition, investigation into the relationship between hemispheric dominance for language and lesion type and severity showed that LI values were inversely correlated with severity of LH damage for both fTCD and fMRI, in cortical but not in periventricular lesions. As shown by the left HSS (that measures degree of cortical and subcortical extension of unilateral brain lesions), right hemisphere language dominance is significantly associated with more severe brain damage of cortical and subcortical structures in the LH. This finding agrees with previous studies conducted with dichotic listening paradigms (Brizzolaro *et al.*, 2002; Bulgheroni *et al.*, 2004; Chilosi *et al.*, 2005), in which a significant correlation between extent of LH damage and negative LI was found. Also in a study by Lidzba *et al.* 2008, lesion size correlated significantly with the degree of frontal right hemisphere activation during an fMRI silent word generation task.

Given that the mean left HSS was significantly lower in PWM, compared to CDGM lesions, it is not clear which factors might explain the lack of relationship between lesion severity and language organization in patients with PWM. This could be due to difficulties in untangling severity from type/timing of lesions (in terms of pre- vs perinatal insult). While CDGM lesions mainly occur at around term age, PWM lesions are more frequent during preterm period.

In a study of Raja Beharelle *et al.* (2010), patients with periventricular lesions presented significantly more left frontal activation compared to patients with cortical vascular lesions. According to Staudt *et al.*, 2001, the site of PWM lesion is an important determinant of language (re)organization. In fact, even small periventricular damage may lead to interhemispheric (re)organization if the lesion involves the facial motor tract.

In conclusion, this study, the first conducted on healthy and focal brain-damaged children and young adults, using both fTCD and fMRI, provides further evidence that fTCD is a suitable method for studying neurofunctional organization of language. Strong concordance between measurement of language lateralization with fTCD and fMRI may open new perspectives for the study of brain language organization in normal and clinical populations across a wide range of developmental ages. As outlined by several authors, fTCD may be a valid alternative to fMRI, as an easily applicable tool for large-scale studies of



patients with developmental brain diseases. Given its poor spatial resolution, the concomitant use of fMRI could be reserved to those cases where a more precise identification of cortical and subcortical regions of interest is required, such as in pre-operative patients. This conclusion should be supported by further experimental evidence on larger samples and with comparable methods of data acquisition and analysis. Regarding the theoretical implications of this study, it leaves unanswered some unresolved questions on the limits of brain plasticity and the degree of predetermined bias to hemispheric laterality for language. In this perspective, extensive neurofunctional investigation of language (re)organization after early brain damage may contribute to advance knowledge of pathophysiological mechanisms at work during development. From a clinical perspective, our findings suggest that, in patients with congenital focal brain injury, severity and type of brain lesion, and especially, extent of CDGM damage to the LH, might be indicative of atypical language dominance, which could have negative effects on language outcome. These risk factors, thoroughly assessed by non-invasive techniques of structural and functional exploration of the brain, should be considered when planning therapeutic intervention.

## Acknowledgements

We thank all the subjects who kindly accepted to take part in this study and their parents. This research was funded by the Mariani Foundation (Grant R-10-82 to AMC) and by the European Union Grants Framework 7 – European Research Council (FP7–ERC) ‘Early cortical sensory plasticity and adaptability in human adults (ESCPLAIN)’. We thank Vincent Corsentino for reviewing the English of this manuscript, Giuseppe Rossi for statistical advises, and Silvia Perazza and Paola Bruna Paolicelli for referral of some patients and Professor Dorothy Bishop for providing the Animation Description paradigm and instructions about related experimental procedures.

## References

- Abou-Khalil, B. (2007). Methods for determination of language dominance: the Wada test and proposed noninvasive alternatives. *Current Neurology and Neuroscience Reports*, 7, 483–490. <https://doi.org/10.1007/s11910-007-0075-6>
- Aldenkamp, A. P., Boon, P. A., Deblaere, K., Achten, E., Backes, W. H., Boon, P., . . . Wilmink, J. (2003). Usefulness of language and memory testing during intracarotid amobarbital testing: Observations from an fMRI study. *Acta Neurologica Scandinavica*, 108(3), 147–152. <https://doi.org/10.1034/j.1600-0404.2003.00116.x>
- Binder, J. R., Swanson, S. J., Hammeke, T. A., Morris, G. L., Mueller, W. M., Fischer, M., . . . Haughton, V. M. (1996). Determination of language dominance using functional MRI: A comparison with the Wada test. *Neurology*, 46, 978–984. <https://doi.org/10.1212/WNL.46.4.978>
- Bishop, D. V., Holt, G., Whitehouse, A. J., & Groen, M. (2014). No population bias to left-hemisphere language in 4-year-olds with language impairment. *PeerJ*, 2, e507. <https://doi.org/10.7717/peerj.507>
- Bishop, D. V., Watt, H., & Papadatou-Pastou, M. (2009). An efficient and reliable method for measuring cerebral lateralization during speech with functional transcranial Doppler ultrasound. *Neuropsychologia*, 47, 587–590. <https://doi.org/10.1016/j.neuropsychologia.2008.09.013>
- Boynton, G. M., Engel, S. A., Glover, G. H., & Heeger, D. J. (1996). Linear systems analysis of functional magnetic resonance imaging in human V1. *Journal of Neuroscience*, 16, 4207–4221. Retrieved from <http://www.jneurosci.org/content/16/13/4207>

- Brizzolara, D., Pecini, C., Brovedani, P., Ferretti, G., Cipriani, P., & Cioni, G. (2002). Timing and type of congenital brain lesion determine different patterns of language lateralization in hemiplegic children. *Neuropsychologia*, *40*, 620–632. [https://doi.org/10.1016/S0028-3932\(01\)00158-0](https://doi.org/10.1016/S0028-3932(01)00158-0)
- Bulgheroni, S., Nichelli, F., Erbetta, A., Bagnasco, I., & Riva, D. (2004). Verbal Dichotic Listening and manual performance in children with congenital unilateral brain lesion. *Neuropsychology*, *18*, 748–755. <https://doi.org/10.1037/0894-4105.18.4.748>
- Carlsson, G., Hugdahl, K., Uvebrant, P., Wiklund, L. M., & von Wendt, L. (1992). Pathological left-handedness revisited: Dichotic listening in children with left vs right congenital hemiplegia. *Neuropsychologia*, *30*, 471–481. [https://doi.org/10.1016/0028-3932\(92\)90094-3](https://doi.org/10.1016/0028-3932(92)90094-3)
- Chilosi, A. M., Comparini, A., Cristofani, P., Turi, M., Berrettini, S., Forli, F., . . . Cioni, G. (2014). Cerebral lateralization for language in deaf children with cochlear implantation. *Brain & Language*, *129*, 1–6. <https://doi.org/10.1016/j.bandl.2013.12.002>
- Chilosi, A. M., Pecini, C., Cipriani, P., Brovedani, P., Brizzolara, D., Ferretti, G., . . . Cioni, G. (2005). Atypical language lateralization and early linguistic development in children with focal brain lesions. *Developmental Medicine and Child Neurology*, *47*, 725–730. <https://doi.org/10.1017/S0012162205001532>
- Deppe, M., Knecht, S., Henningsen, H., & Ringelstein, E. B. (1997). AVERAGE: A Windows program for automated analysis of event related cerebral blood flow. *Journal of Neuroscience Methods*, *75*(2), 147–154. [https://doi.org/10.1016/S0165-0270\(97\)00067-8](https://doi.org/10.1016/S0165-0270(97)00067-8)
- Deppe, M., Knecht, S., Papke, K., Lohmann, H., Fleischer, H., Heindel, W., . . . Henningsen, H. (2000). Assessment of hemispheric language lateralization: A comparison between fMRI and fTCD. *Journal of Cerebral Blood Flow and Metabolism*, *20*, 263–268. <https://doi.org/10.1097/00004647-200002000-00006>
- Deppe, M., Ringelstein, E. B., & Knecht, S. (2004). The investigation of functional brain lateralization by transcranial Doppler sonography. *NeuroImage*, *21*, 1124–1146. <https://doi.org/10.1016/j.neuroimage.2003.10.016>
- Efron, B., & Tibshirani, R. (1991). Statistical data analysis in the computer age. *Science*, *253*, 390–395. <https://doi.org/10.1126/science.253.5018.390>
- Fernandes, M. A., Smith, M. L., Logan, W., Crawley, A., & McAndrews, M. P. (2006). Comparing language lateralization determined by dichotic listening and fMRI activation in frontal and temporal lobes in children with epilepsy. *Brain & Language*, *96*(1), 106–114. <https://doi.org/10.1016/j.bandl.2005.06.006>
- Fiori, S., Cioni, G., Klingels, K., Ortibus, E., Van Gestel, L., Rose, S., . . . Guzzetta, A. (2014). Reliability of a novel, semi-quantitative scale for classification of structural brain magnetic resonance imaging in children with cerebral palsy. *Developmental Medicine and Child Neurology*, *56*, 839–845. <https://doi.org/10.1111/dmcn.12457>
- Fiori, S., & Guzzetta, A. (2015). Plasticity following early-life brain injury: insights from quantitative MRI. *Seminars in Perinatology*, *39*(2), 141–146. <https://doi.org/10.1053/j.semperi.2015.01.007>
- Fleiss, J. L. (1981). *Statistical methods for rates and proportions* (2nd ed.). New York, NY; Chichester, UK: Wiley.
- Gibo, H., Carver, C. C., Rhoton, A. L., Lenkey, C., & Mitchell, R. J. (1981). Microsurgical anatomy of the middle cerebral artery. *Journal of Neurosurgery*, *54*(2), 151–169. <https://doi.org/10.3171/jns.1981.54.2.0151>
- Guzzetta, A., Pecini, C., Biagi, L., Tosetti, M., Brizzolara, D., Chilosi, A., . . . Cioni, G. (2008). Language organisation in left perinatal stroke. *Neuropediatrics*, *39*(3), 157–163. <https://doi.org/10.1055/s-0028-1085465>
- Haag, A., Moeller, N., Knake, S., Hermsen, A., Oertel, W. H., Rosenow, F., & Hamer, H. M. (2010). Language lateralization in children using functional transcranial Doppler sonography. *Developmental Medicine and Child Neurology*, *52*, 331–336. <https://doi.org/10.1111/j.1469-8749.2009.03362.x>
- Haag, A., Preibisch, C., Sure, U., Knake, S., Heinze, S., Krakow, K., . . . Hamer, H. M. (2006). Right hemispheric language dominance in a right-handed male with a right frontal tumor shown by

- functional transcranial Doppler sonography. *Epilepsy and Behavior*, 8(1), 336–340. <https://doi.org/10.1016/j.yebeh.2005.10.016>
- Hattemer, K., Plate, A., Heverhagen, J. T., Haag, A., Keil, B., Klein, K. M., . . . Knake, S. (2011). Determination of hemispheric dominance with mental rotation using functional transcranial Doppler sonography and fMRI. *Journal of Neuroimaging*, 21(1), 16–23. <https://doi.org/10.1111/j.1552-6569.2009.00402.x>
- Hodgson, J. C., & Hudson, J. M. (2016). Atypical speech lateralization in adults with developmental coordination disorder demonstrated using functional transcranial Doppler ultrasound. *Journal of Neuropsychology*, 11(1), 1–13. <https://doi.org/10.1111/jnp.12102>
- Illingworth, S., & Bishop, D. V. M. (2009). Atypical cerebral lateralisation in adults with compensated developmental dyslexia demonstrated using functional transcranial Doppler ultrasound. *Brain and Language*, 111(1), 61–65. <https://doi.org/10.1016/j.bandl.2009.05.002>
- Isaacs, K. L., Barr, W. B., Nelson, P. K., & Devinsky, O. (2006). Degree of handedness and cerebral dominance. *Neurology*, 66, 1855–1858. <https://doi.org/10.1212/01.wnl.0000219623.28769.74>
- Jansen, A., Floel, A., Deppe, M., van Randenborgh, J., Drager, B., Kanowski, M., & Knecht, S. (2004). Determining the hemispheric dominance of spatial attention: A comparison between fTCD and fMRI. *Human Brain Mapping*, 23(3), 168–180. <https://doi.org/10.1002/hbm.20055>
- Knake, S., Haag, A., Hamer, H. M., Dittmer, C., Bien, S., Oertel, W. H., & Rosenow, F. (2003). Language lateralization in patients with temporal lobe epilepsy: A comparison of functional transcranial Doppler sonography and the Wada test. *NeuroImage*, 19, 1228–1232. <https://doi.org/10.1080/1357650X.2014.914950>
- Knecht, S., Deppe, M., Ebner, A., Henningsen, H., Huber, T., Jokeit, H., & Ringelstein, E. B. (1998). Noninvasive determination of language lateralization by functional transcranial Doppler sonography: A comparison with the Wada test. *Stroke*, 29(1), 82–86. <https://doi.org/10.1161/01.STR.29.1.82>
- Knecht, S., Drager, B., Floel, A., Lohmann, H., Breitenstein, C., Deppe, M., . . . Ringelstein, E. B. (2001). Behavioural relevance of atypical language lateralization in healthy subjects. *Brain*, 124 (Pt 8), 1657–1665. <https://doi.org/10.1093/brain/124.8.1657>
- Knecht, M., & Lidzba, K. (2016). Processing verbal morphology in patients with congenital left-hemispheric brain lesions. *Brain & Language*, 157–158, 25–34. <https://doi.org/10.1016/j.bandl.2016.04.011>
- Krageloh-Mann, I., & Horber, V. (2007). The role of magnetic resonance imaging in furthering understanding of the pathogenesis of cerebral palsy. *Developmental Medicine and Child Neurology*, 49, 948. <https://doi.org/10.1111/j.1469-8749.2007.00948.x>
- Landis, JR, & Koch, G.G. (1977). The measurement of observer agreement for categorical data. *Biometrics*, 33, 159–174. Retrieved from <http://www.jstor.org/stable/2529310>
- Lazar, R. M., Marshall, R. S., Pile-Spellman, J., Duong, H. C., Mohr, J. P., Young, W. L., . . . DeLaPaz, R. L. (2000). Interhemispheric transfer of language in patients with left frontal cerebral arteriovenous malformation. *Neuropsychologia*, 38, 1325–1332. [https://doi.org/10.1016/S0028-3932\(00\)00054-3](https://doi.org/10.1016/S0028-3932(00)00054-3)
- Lee, J., & Fung, K. P. (1993). Confidence interval of the kappa coefficient by bootstrap resampling. *Psychiatry Research*, 49(1), 97–98. [https://doi.org/10.1016/0165-1781\(93\)90033-D](https://doi.org/10.1016/0165-1781(93)90033-D)
- Lidzba, K., & Staudt, M. (2008). Development and (re)organization of language after early brain lesions: Capacities and limitation of early brain plasticity. *Brain and Language*, 106(3), 165–166. <https://doi.org/10.1016/j.bandl.2008.05.003>
- Lidzba, K., Wilke, M., Staudt, M., Krageloh-Mann, I., Grodd, W. (2008). Reorganization of the cerebro-cerebellar network of language production in patients with congenital left-hemispheric brain lesions. *Brain and Language*, 106(3), 204–210. <https://doi.org/10.1016/j.bandl.2007.11.003>
- Liegeois, F., Connelly, A., Cross, J. H., Boyd, S. G., Gadian, D. G., Vargha-Khadem, F., & Baldeweg, T. (2004). Language reorganization in children with early-onset lesions of the left hemisphere: An fMRI study. *Brain*, 127(Pt 6), 1229–1236. <https://doi.org/10.1093/brain/awh159>

- Maldjian, J. A., Liu, W. C., Hirschorn, D., Murthy, R., & Semanczuk, W. (1997). Wavelet transform-based image compression for transmission of MR data. *AJR American Journal of Roentgenology*, *169*(1), 23–26. <https://doi.org/10.2214/ajr.169.1.9207495>
- Meyer, G. F., Spray, A., Fairlie, J. E., & Uomini, N. T. (2014). Inferring common cognitive mechanisms from brain blood-flow lateralization data: A new methodology for fTCD analysis. *Frontiers in Psychology*, *5*, 1–15. <https://doi.org/10.3389/fpsyg.2014.00552>
- Milner, B., Branch, C., & Rasmussen, T. (1962). A study of short term memory after intracarotid injection of sodium amytal. *Transactions of the American Neurological Association*, *87*, 224–226.
- Muller, R. A., Behen, M. E., Rothermel, R. D., Muzik, O., Chakraborty, P. K., & Chugani, H. T. (1999). Brain organization for language in children, adolescents, and adults with left hemisphere lesion: A PET study. *Progress in Neuropsychopharmacology & Biological Psychiatry*, *23*, 657–668. [https://doi.org/10.1016/S0278-5846\(99\)00024-X](https://doi.org/10.1016/S0278-5846(99)00024-X)
- Oldfield, R. C. (1971). The assessment and analysis of handedness: The Edinburgh inventory. *Neuropsychologia*, *9*(1), 97–113. [https://doi.org/10.1016/0028-3932\(71\)90067-4](https://doi.org/10.1016/0028-3932(71)90067-4)
- Payne, H., Gutierrez-Sigut, E., Subik, J., Woll, B., & MacSweeney, M. (2015). Stimulus rate increases lateralisation in linguistic and non-linguistic tasks measured by functional transcranial Doppler sonography. *Neuropsychologia*, *72*, 59–69. <https://doi.org/10.1016/j.neuropsychologia.2015.04.019>
- Pecini, C., Biagi, L., Brizzolara, D., Cipriani, P., Di Lieto, M. C., Guzzetta, A., . . . Chilosi, A. M. (2011). How many functional brains in developmental dyslexia? When the history of language delay makes the difference. *Cognitive and Behavioral Neurology*, *24*(2), 85–92. <https://doi.org/10.1097/WNN.0b013e318222a4c2>
- Raja Beharelle, A., Dick, A. S., Josse, G., Solodkin, A., Huttenlocher, P. R., Levine, S. C., & Small, S. L. (2010). Left hemisphere regions are critical for language in the face of early left focal brain injury. *Brain*, *133*, 1707–1716. <https://doi.org/10.1093/brain/awq104>
- Ringelstein, E. B., Kahlscheuer, B., Niggemeyer, E., & Otis, S. M. (1990). Transcranial Doppler sonography: Anatomical landmarks and normal velocity values. *Ultrasound in Medicine and Biology*, *16*, 745–761. [https://doi.org/10.1016/0301-5629\(90\)90039-f](https://doi.org/10.1016/0301-5629(90)90039-f)
- Rutten, G. J., Ramsey, N. F., van Rijen, P. C., Alpherts, W. C., & van Veelen, C. W. (2002). fMRI-determined language lateralization in patients with unilateral or mixed language dominance according to the Wada test. *NeuroImage*, *17*(1), 447–460. <https://doi.org/10.1006/nimg.2002.1196>
- Seghier, M. L. (2008). Laterality index in functional MRI: Methodological issues. *Magnetic Resonance Imaging*, *26*, 594–601. <https://doi.org/10.1016/j.mri.2007.10.010>
- Somers, M., Neggers, S. F., Diederer, K. M., Boks, M. P., Kahn, R. S., & Sommer, I. E. (2011). The measurement of language lateralization with functional transcranial doppler and functional MRI: A critical evaluation. *Frontiers in Human Neuroscience*, *5*, 31. <https://doi.org/10.3389/fnhum.2011.00031>
- Staudt, M., Grodd, W., Niemann, G., Wildgruber, D., Erb, M., & Krageloh-Mann, I. (2001). Early left periventricular brain lesions induce right hemispheric organization of speech. *Neurology*, *57*(1), 122–125. <https://doi.org/10.1212/WNL.57.1.122>
- Stroobant, N., Van Boxtael, J., & Vingerhoets, G. (2011). Language lateralization in children: A functional transcranial Doppler reliability study. *Journal of Neurolinguistics*, *24*, 14–24. <https://doi.org/10.1016/j.jneuroling.2010.07.003>
- Tillema, J. M., Byars, A. W., Jacola, L. M., Schapiro, M. B., Schmithorst, V. J., Szafarski, J. P., & Holland, S. K. (2008). Cortical reorganization of language functioning following perinatal left MCA stroke. *Brain and Language*, *105*(2), 99–111. <https://doi.org/10.1016/j.bandl.2007.07.127>
- Wellmer, J., Weber, B., Weis, S., Klaver, P., Urbach, H., Reul, J., . . . Elger, C. E. (2008). Strongly lateralized activation in language fMRI of atypical dominant patients-implications for presurgical work-up. *Epilepsy Research*, *80*(1), 67–76. <https://doi.org/10.1016/j.eplepsyres.2008.03.005>

Whitehouse, A. J., & Bishop, D. V. (2008). Cerebral dominance for language function in adults with specific language impairment or autism. *Brain*, *131*, 3193–3200. <https://doi.org/10.1093/brain/awn266>

Received 12 September 2016; revised version received 26 April 2017

### **Supporting Information**

The following supporting information may be found in the online edition of the article:

**Table S1.** Individual patient data on lesions characteristics and language lateralization indices.

**Table S2.** Individual data of control subjects on language lateralization indices.